

CASE STUDY

Presenting Reason -

22 year old South Asian female, came into clinic today for an urgent review for sudden loss of vision in the left eye. There has been no history of trauma, headaches or transient vision loss. Upon further questioning, the patient attempted to do a hand stand, which is something they do not usually do and they noticed a sudden drop in vision after that. There is no complaints of shadows in visual field or flashing lights as well.

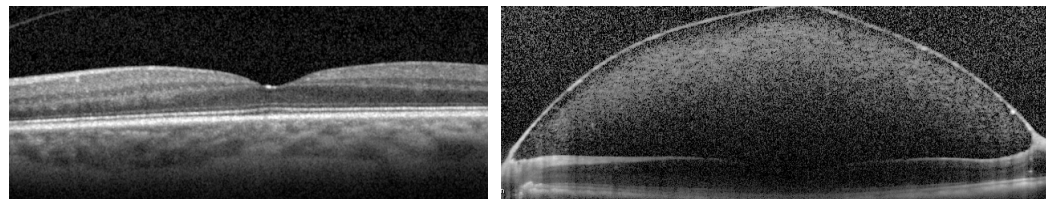
Medical History -

- Nil Allergies
- Unremarkable medical history
- Unremarkable family history
- **Current Medication:** nil medications taken

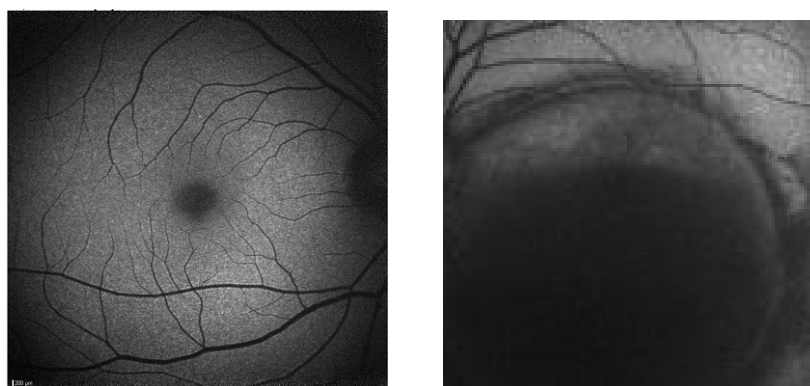
Clinical Tests: -

OCT

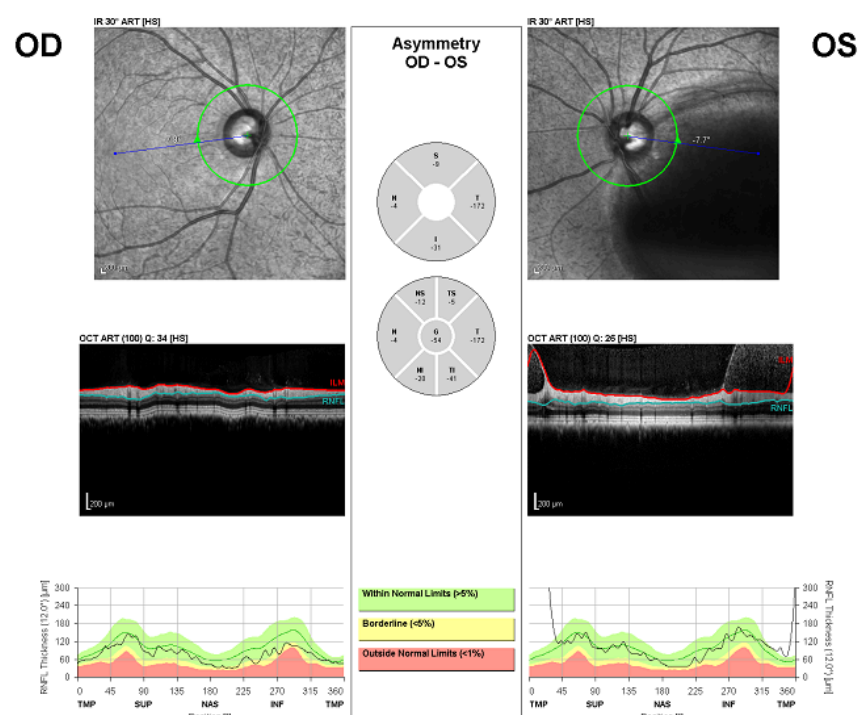
Macular scan



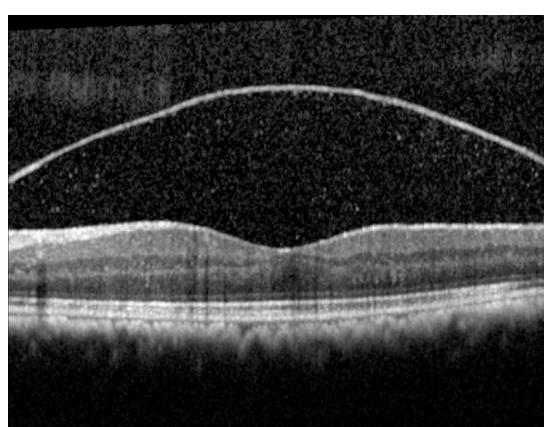
Fundus
Autofluorescence



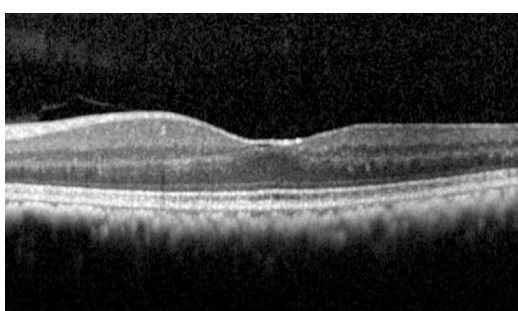
Optic Nerve
(RFNL scan)



OCT mac scan L eye
after 2 months



after 5 months



Clinical Exam -

Vision c gls R 6/4 (N5) L 6/60 (<N48)
Glasses Prescription
R -0.25DS / +0.75DC x 170
L -0.50DS / +0.50DC x 100
IOP c Goldmann Applanation R 15mmHg L 17mmHg
Nil RAPD, Angles Open
Cover test and ocular motility full

DIAGNOSIS: Valsalva Retinopathy

The pre-retinal, blister-like haemorrhage on the OCT macular scan alongside the sudden increase in intra-thoracic pressure from the patient doing a handstand were typical signs pointing towards the patient having valsalva pathology,

What is Valsalva Retinopathy?

Valsalva Retinopathy is a condition that is caused by the spontaneous rupturing of the superficial retinal capillaries when there is a sudden increase of intra-thoracic or intra-abdominal pressure. Activities which can cause valsalva retinopathy can include, but not limited to:

- intense coughing, episodes and vomiting,
- lifting heavy weights
- straining for a bowel movement
- sexual intercourse

Signs and Symptoms?

The primary sign is a sudden painless visual loss or scotoma after a doing an activity like that listed above. Often this is a unilateral condition, but it can occur bilaterally as well. Fundus examination can highlight a pre-retinal hemorrhage typically located in the pre-macular area, below the internal limiting membrane which can lift up to form an arc like membrane that settles down (as seen in the progression images of our case study), Fluorescein angiography can be used to rule out any neovascularization or active leaks as well.

Prognosis?

Management of this condition is often conservative as the recovery is often spontaneous within a few weeks to months. Recommending a cessation of anti-coagulants and strenuous activities is beneficial as well. If vision has not returned to normal after this time, a review with a vitreo-retinal specialist can be warranted to for possible surgical interventions. In our patient for this case the vision returned to 6/6 after 5 months of monitoring them.

Treating Ophthalmologist for this case: Dr Terence Tan

PARRAMATTA

(02) 9635 7077

152 Marsden Street
Parramatta, NSW 2150

CASTLE HILL

(02) 9634 6364

19/7-9 Barwell Ave
Castle Hill, NSW 2154

PENRITH

(02) 4731 1811

295 High Street (Evans Street
Entrance) Penrith, NSW 2750

M
MARSDEN
EYE
SPECIALISTS